



PATIENT

Asher Timmons

SPECIES

Canine

BREED

Poodle Mix

SEX

MN

AGE

5

WEIGHT

38.6

INTERPRETED BY

R. McKenzie Daniel,
DVM, DABVP
(Canine and Feline)

IMAGING PERFORMED BY

Jenn

HOSPITAL NAME

Rockaway Animal
Hospital

REFERRING VET

Dr Schiess

INVOICE

22930

DATE

11/11/2025

PRESENTING CLINICAL SIGNS

presented for Addisonian crisis lethargy shocky decreased appetite azotemia hyperkalemia r/o additional underlying dz Current meds Percorten Dex SP IVF Pantoprazole

Abnormal PE/Chem/CBC/UA Results: Eosinophilia 1.28 Creat 2.5 BUN 66 Phos 11.4 K 8.5 Na 148 Na/K ratio 8.5 ACTH stim supports addisons

ULTRASONOGRAPHIC EXAMINATION OF THE ABDOMEN

Urinary System

The urinary bladder, trigone, cystourethral junction, and visible pelvic urethra exhibited normal thickness and tone. Anechoic urine was present in the lumen with no evidence of urine/lumen sediment, mineral, or calculi. The ureteral papillae were normal. The ureters were not visible which is normal. No evidence of inflammatory or neoplastic changes was noted.

Normal size and margination were present in the kidneys. A normal 1:3 cortex / medulla ratio and normal corticomedullary definition were maintained. The echogenicity of the cortex was similar to or slightly less than normal liver parenchyma while the medulla echogenicity was hypoechoic to the cortex with no evidence of pelvic dilation. The left kidney measured 5.3 cm in length. The right kidney measured 6.2 cm in length.

The area of the aortic trifurcation was free of pathology.

The area of the residual prostate appeared normal and free of pathology.

Adrenal Glands

The bilateral adrenal glands were not definitively visualized exhibiting subjective subnormal size, consistent with patient history.

Spleen

The spleen exhibited normal to mild subnormal size with a finely textured and homogenous parenchyma which was hyperechoic to the liver and renal cortical parenchyma. The capsule was smooth and regular without apparent expansion. The splenic vasculature at the hilus was normal in volume with no evidence of congestion or thrombosis. Acute to chronic inflammatory, neoplastic, or benign parenchyma changes were not noted.

Liver/Gallbladder

The liver was subjectively normal in size, structure, and contour. The liver parenchyma was uniform and hypoechoic to the spleen with a mild coarse echotexture. Normal vascular volume. The hepatic and portal vasculature were normal in appearance without signs of congestion. The gallbladder was non-distended in size with thin walls and primarily anechoic luminal content. The cystic and common bile ducts were normal.

Gastrointestinal

The stomach presented intact wall layering with a normal wall layer ratio. The lumen of the stomach was empty with no signs of ileus, obstruction or foreign material.

The small intestine presented intact wall layering with 1:3 muscularis/mucosa ratio. The lumen of the small intestine was empty with no signs of mechanical/metabolic ileus, obstruction or foreign material.



PATIENT

Normal visible colon wall layers were present with apparent formed feces in lumen.

Asher Timmons

Pancreas

The parenchyma of the left limb, body and right limb of the pancreas presented isoechoic to the adjacent omental fat. A normal curvilinear capsule contour of the pancreas was present. The visible pancreatic duct was normal. No signs of active inflammation or neoplastic disease was evident.

SPECIES

Canine

Free Abdomen

No omental masses, overt lymphadenopathy or peritoneal effusion was present.

BREED

Poodle Mix

ULTRASONOGRAPHIC FINDINGS

Primary

SEX

- Non-visualized adrenal glands - consistent with patient history
- Normal gastrointestinal tract with subjective mild gastritis
- Normal bilateral kidneys

MN

AGE

5

INTERPRETATION OF THE FINDINGS & FURTHER RECOMMENDATIONS

No evidence of significant visceral pathology with abdominal presentation consistent with Addisonian crisis given patient history. Supportive care for Addisonian crisis with clinical monitoring of gastrointestinal signs and renal parameters is recommended.

WEIGHT

38.6

INTERPRETED BY

R. McKenzie Daniel,
DVM, DABVP
(Canine and Feline)

IMAGING PERFORMED BY

Jenn

HOSPITAL NAME

Rockaway Animal
Hospital

REFERRING VET

Dr Schiess

INVOICE

22930

DATE

11/11/2025



PATIENT

Asher Timmons

SPECIES

Canine

BREED

Poodle Mix

SEX

MN

AGE

5

WEIGHT

38.6

INTERPRETED BY

R. McKenzie Daniel,
DVM, DABVP
(Canine and Feline)

IMAGING PERFORMED BY

Jenn

HOSPITAL NAME

Rockaway Animal
Hospital

REFERRING VET

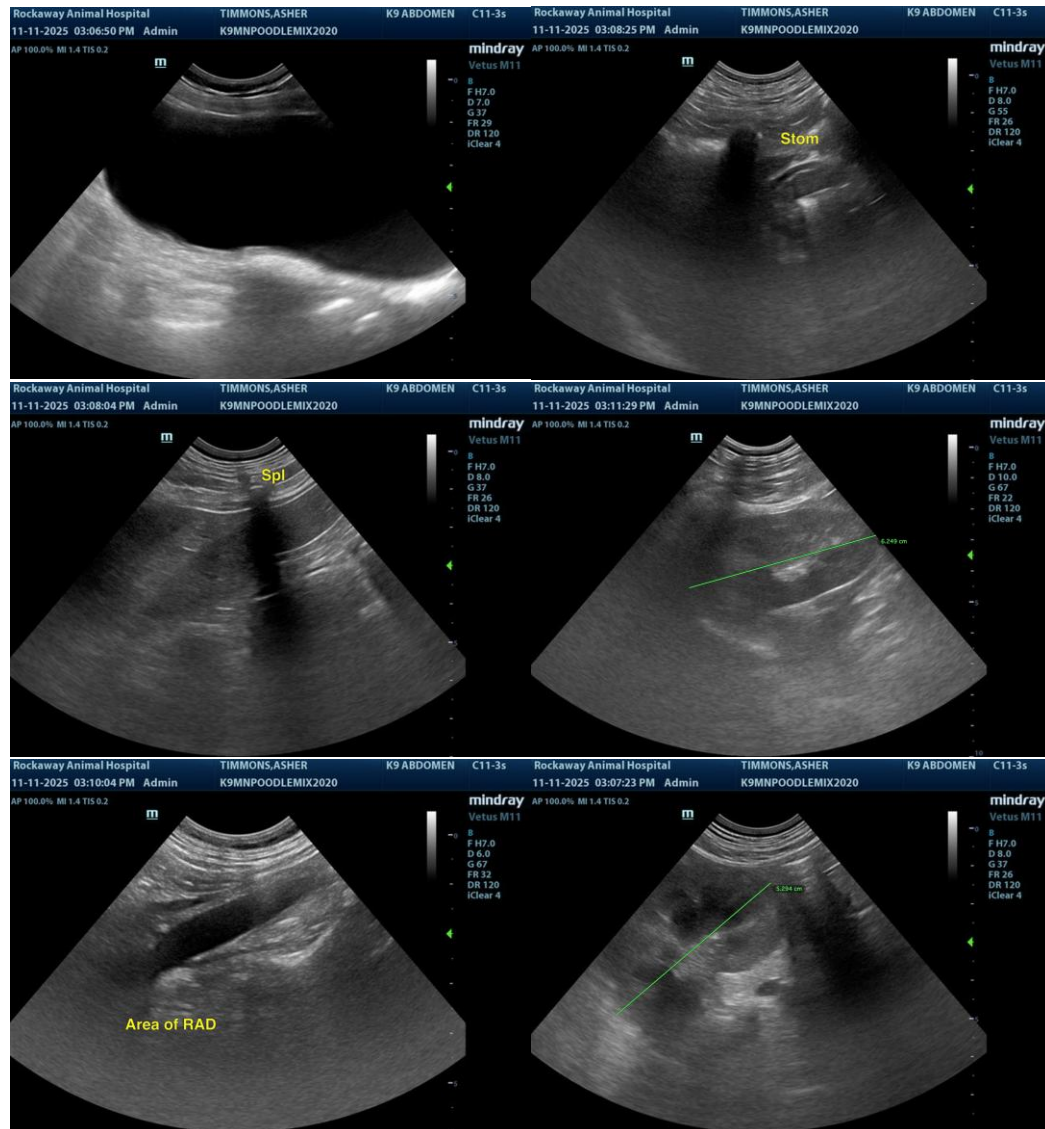
Dr Schiess

INVOICE

22930

DATE

11/11/2025





PATIENT

Asher Timmons

SPECIES

Canine

BREED

Poodle Mix

SEX

MN

AGE

5

WEIGHT

38.6

INTERPRETED BY

R. McKenzie Daniel,
DVM, DABVP
(Canine and Feline)

IMAGING PERFORMED BY

Jenn

HOSPITAL NAME

Rockaway Animal
Hospital

REFERRING VET

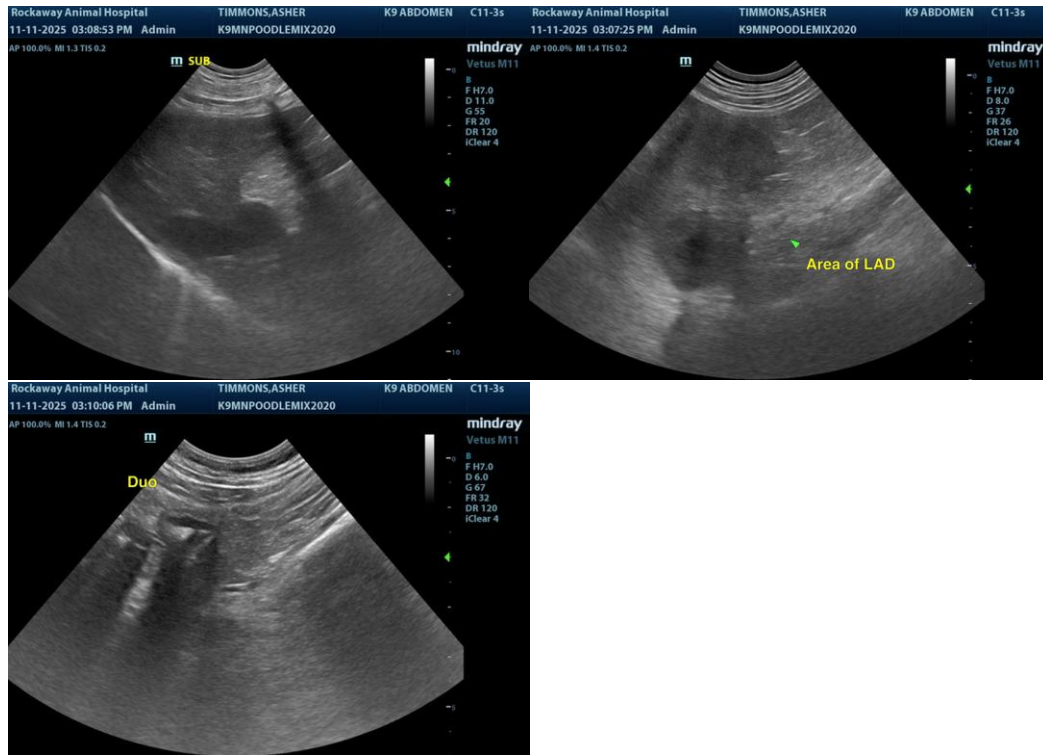
Dr Schiess

INVOICE

22930

DATE

11/11/2025



The information and recommendations provided are based on the images presented by the referring veterinarian/sonographer. No evaluation can be communicated regarding pathology that was not visible in the image/video clips provided.

Thank you for this referral. If the clinical or image interpretation does not parallel your findings or if I can be of any further assistance, please contact me.

R. McKenzie Daniel, DVM, DABVP (Canine/Feline Practice)
info@sonopath.com